

Partial Agenesis of the Lower Lateral Cartilage in Aesthetic Rhinoplasty: A Case Report

Seyed Yavar Shams Hojjati¹, Reza Sharifi¹, Tania Yeganeh², Sepehr Shirzadeh^{1*}

1. Department of Plastic Surgery, Faculty of Medicine, Mashhad University of Medical Sciences, Mashhad, Iran
2. Department of Radiology, Faculty of Medicine, Mashhad University of Medical Sciences, Mashhad, Iran

ABSTRACT

Congenital absence of nasal cartilage elements is a rare finding in patients undergoing elective rhinoplasty. We report a case of a 27-year-old woman with no prior trauma, respiratory complaints, or syndromic features, who presented for aesthetic rhinoplasty. Intraoperatively, congenital agenesis of the left middle and lateral crura of the lower lateral cartilage (LLC) was identified. Reconstruction was performed using septal cartilage harvested during submucosal resection. The patient had an excellent aesthetic and functional outcome. This case highlights the importance of surgeon preparedness for unexpected congenital anomalies, even in cosmetic settings.

KEYWORDS

Case report; Rhinoplasty; Lower Lateral Cartilage

Please cite this paper as:

Shams Hojjati SY, Sharifi R, Yeganeh T, Shirzadeh S. Partial Agenesis of the Lower Lateral Cartilage in Aesthetic Rhinoplasty: A Case Report. *World J Plast Surg.* 2025;14(4):1-4.
doi: 10.61186/wjps.14.4.**

INTRODUCTION

Congenital anomalies of the nasal cartilaginous framework represent a unique challenge in both functional and aesthetic rhinoplasty. While most nasal deformities are acquired through trauma or aging, true congenital absence of lower lateral cartilage components remains exceptionally rare and has been reported only sporadically in isolated case reports¹.

These anomalies typically present in two broad categories: syndromic associations and isolated defects. Syndromic cases account for approximately 85% of reported anomalies and include conditions such as Binder syndrome (maxillonasal dysplasia), frontonasal dysplasia sequence, and CHARGE association. Isolated defects, which comprise the remaining 15% of cases, include agenesis of the middle or lateral crus, medial crus hypoplasia, or complete absence of the alar cartilage. From an embryological perspective, the lower lateral cartilage originates from neural crest cells during weeks 7 to 10 of gestation. The lateral nasal process forms the lateral and middle crura, while the medial nasal process gives rise to the medial crus and columella. Molecular studies have implicated disruptions in signaling pathways such as fibroblast growth factor 2 (FGF-2) and Sonic Hedgehog (SHH) in isolated cartilage agenesis^{2,3}.

*Corresponding Author:

Sepehr Shirzadeh;

Plastic Surgery Resident,
Department of Plastic Surgery,
Faculty of Medicine, Mashhad
University of Medical Sciences,
Mashhad, Iran

Email: sepehr.sh.2009@gmail.com

Received: ***

Accepted: ***

This case report describes an unexpected intraoperative discovery of isolated agenesis of the left middle and lateral crura during aesthetic rhinoplasty and discusses the surgical management and clinical implications of this rare finding.

CASE PRESENTATION

A 27-year-old woman presented for aesthetic rhinoplasty in Mashhad, Iran, in 2025. She had no history of nasal trauma, previous surgery, respiratory dysfunction, or systemic/genetic disorders.

Preoperative Assessment

- Negative Cottle maneuver
- Mild dorsal hump with no visible nasal asymmetry
- No septal deviation noted on anterior rhinoscopy (Fig. 1)

Intraoperative Findings

Open rhinoplasty revealed normal right lower lateral cartilage anatomy. However, on the left side, the middle and lateral crura of the LLC were completely absent, with only the medial crus preserved.

Reconstruction Technique

1. Cartilage Harvesting: Septal cartilage was harvested via submucosal resection, preserving the L-strut.
2. Graft Fabrication: The harvested cartilage was carved into two grafts, each approximately 5×10 mm.
3. Fixation: The grafts were sutured to the residual medial crus using 5-0 polydioxanone (PDS) sutures (Fig. 2).

Postoperative Outcome

At two-month follow-up, the patient demonstrated symmetric alar rims, maintained nasal patency, and reported no breathing issues. She rated her satisfaction as 9 out of 10 on the Rhinoplasty Outcome Evaluation (ROE) questionnaire (Fig. 3).

Ethical Approval and Patient Consent

This case report was approved by the Institutional Review Board of Mashhad University of Medical Sciences. Written informed consent was obtained from the patient for publication of this case report and accompanying images.

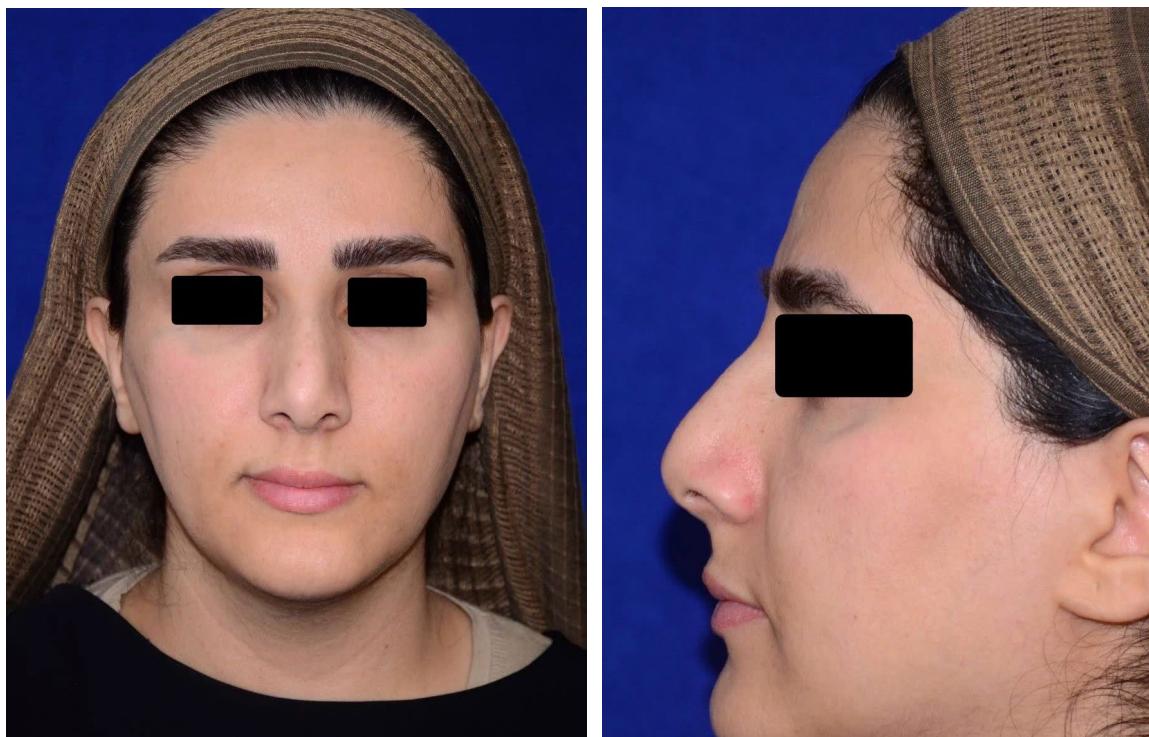

Figure 1: Preoperative frontal view, lateral view

DISCUSSION

Congenital absence of LLC elements represents an exceptionally rare finding in rhinoplasty practice, particularly in patients without associated syndromic features. While alar cartilage deformities are more commonly encountered in the context of cleft lip-nasal deformities or post-traumatic reconstruction, isolated agenesis is seldom diagnosed preoperatively due to its subtle clinical presentation^{4,5}. In our case, despite the complete absence of the left middle and lateral crura, preoperative examination revealed no overt alar asymmetry or functional impairment. This finding underscores the limited sensitivity of visual inspection and palpation in detecting subtle congenital defects and highlights the potential for unexpected anatomical variations even in patients presenting for purely aesthetic indications. The surgical management of such cases requires careful consideration of available reconstructive options. Autologous septal cartilage remains the gold standard for nasal reconstruction due to its favorable structural properties, low resorption rate, and excellent biocompatibility^{6,7}. In our patient, the

use of septal cartilage allowed for precise contouring of the alar margin and restoration of normal nasal architecture with favorable aesthetic and functional outcomes. We considered alternative graft sources including conchal cartilage and costal cartilage, but selected septal cartilage due to its ideal thickness, minimal donor site morbidity, and proximity to the surgical field. The grafts were securely fixed to the residual medial crus using absorbable polydioxanone sutures, which provide adequate support during the healing phase while minimizing long-term foreign body reactions.

This case emphasizes the critical importance of intraoperative flexibility and surgical preparedness when managing unexpected anatomical findings. Despite thorough preoperative assessment, surgeons must be prepared to modify their surgical plan and harvest additional grafts when confronted with unforeseen anatomical variations. From a clinical practice perspective, we recommend that informed consent discussions for aesthetic Rhinoplasty include the possibility of encountering congenital anomalies that may require cartilage grafting and alteration of the surgical plan. Proper documentation

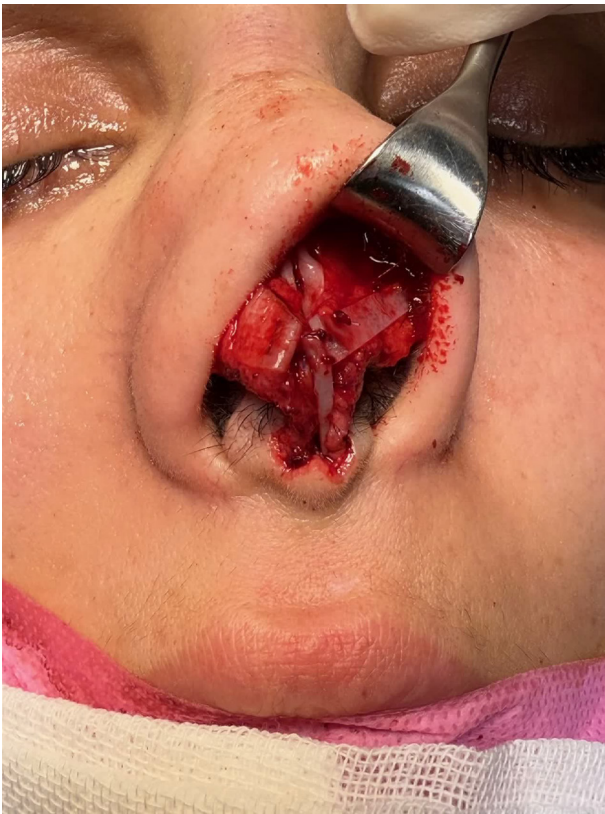

Figure 2: Post Reconstruction

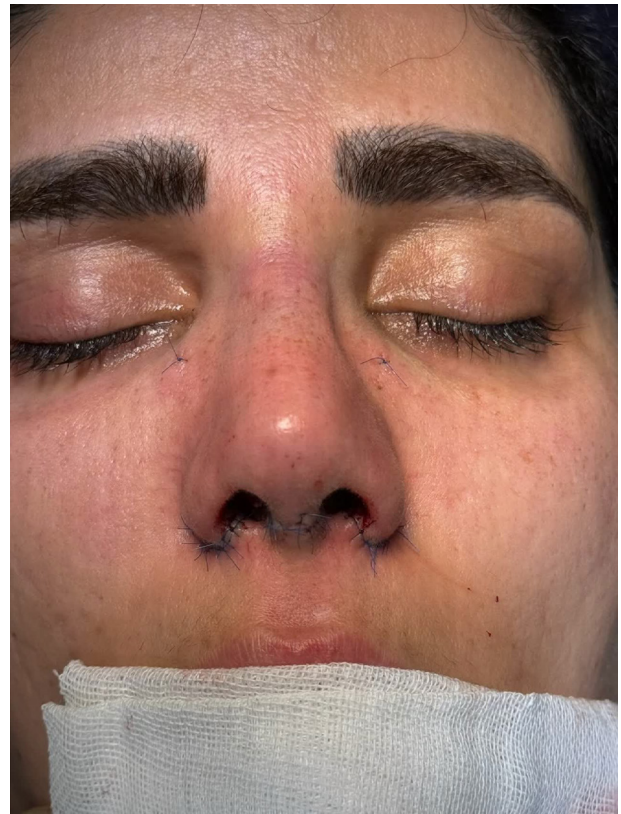


Figure 3: Post Operation

of nasal symmetry and valve function during preoperative evaluation may also help in identifying subtle abnormalities that could suggest underlying cartilaginous anomalies.

From an embryological perspective, isolated agenesis of the middle and lateral crura likely results from localized disruptions in neural crest cell migration or differentiation during critical phases of nasal development. While our patient exhibited no syndromic features or family history of similar anomalies, the unilateral presentation suggests a sporadic developmental event rather than a genetic predisposition. Further research into the molecular mechanisms governing nasal cartilaginous development may enhance our understanding of such rare anomalies and potentially improve preoperative detection methods.

The favorable outcome in our case demonstrates that septal cartilage grafting provides an effective solution for reconstructing congenital defects of the lower lateral cartilage. At two-month follow-up, the patient maintained symmetric alar rims, patent nasal airways, and high satisfaction scores, confirming the durability of the reconstruction during the critical healing phase. Long-term monitoring would be valuable to assess the stability of the results and identify any potential late complications such as graft resorption or distortion.

CONCLUSION

This case illustrates that isolated agenesis of the lower lateral cartilage may present without functional compromise or obvious clinical signs, and can be successfully managed with autologous septal cartilage grafting. The unexpected intraoperative discovery of this rare anomaly in an aesthetic patient underscores the importance of surgical preparedness for anatomical variations. Key recommendations from our experience include:

1. Maintaining a high index of suspicion for congenital cartilaginous anomalies even in patients with normal preoperative examinations.
2. Including the possibility of unexpected anatomical findings and the potential need for cartilage grafting in preoperative informed consent discussions.
3. Ensuring surgical readiness to harvest and fabricate grafts intraoperatively when confronted with unforeseen variations.

4. Utilizing septal cartilage as the primary graft source due to its favorable structural properties and low donor site morbidity.

5. Documenting such rare cases to contribute to the collective understanding of their incidence, presentation, and optimal management strategies. Septal cartilage grafting provides an effective and reliable solution for reconstructing congenital defects of the lower lateral cartilage, with excellent functional and aesthetic outcomes. Surgeons should be prepared to adapt their surgical plan and employ reconstructive techniques when faced with unexpected anatomical findings during rhinoplasty procedures.

ACKNOWLEDGMENTS

No financial source was received for this study.

CONFLICT OF INTEREST

The authors declare no conflict of interests.

REFERENCES

1. Zainy JH. Isolated congenital absence of lower lateral cartilages: a four cases report. *JPRAS Open* 2018;**18**:72–77.
2. Xu J, Iyyanar PPR, Lan Y, et al. Sonic Hedgehog signaling in craniofacial development. *Differentiation* 2023;**133**:60–76.
3. Szabo-Rogers HL, Geetha-Loganathan P, Nimmagadda S, et al. FGF signals from the nasal pit are necessary for normal facial morphogenesis. *Dev Biol* 2008;**318**(2):289–302.
4. Kosins AM, Rollin KD, Sajjadian A, Helms J. Rhinoplasty: congenital deficiencies of the alar cartilage. *Aesthetic Surg J* 2013;**33**(6):799–808.
5. Zainy JH. Isolated congenital absence of lower lateral cartilages: a four cases report. *JPRAS Open* 2018;**16**:72–77.
6. de Pochat VD, Alonso N, Figueredo A, Ribeiro EB, Mendes RR, Meneses JV. The role of septal cartilage in rhinoplasty: cadaveric analysis and assessment of graft selection. *Aesthet Surg J* 2011;**31**(8):891–896.
7. StatPearls [Internet]. Treasure Island (FL): StatPearls Publishing; 2024 Jan-. Rhinoplasty – indications and techniques [Updated 2024 Feb 15; cited 2026 Feb 8]. Available from: <https://www.ncbi.nlm.nih.gov/books/NBK557876/>